



Accurate resection of periacetabular tumor and reconstruction with a novel 3D printing individualized prosthesis

Zheng Guo^{*1}, Hong-Bin Fan¹, Jun Fu¹, Xiao-Kang Li¹, Yu-Lin Hao²

¹The Orthopaedic Oncology Department, Xijing Hospital, the Fourth Military Medical University, Xi'an, Shaanxi, China

²Institute of Metal Research, Chinese Academy of Sciences, Shenyang, Liaoning, China
guozheng@fmmu.edu.cn

Abstract

From December 2010 to May 2016, 8 patients with periacetabular tumor (chondrosarcoma 5 cases and GCT 3 cases) were treated by accurate en-bloc resection and precise reconstruction with a novel 3D printing individualized prosthesis. One case suffered dislocation of hip joint and two cases presented deep venous thrombosis. The mean follow-up period was 37.5 months (range, 5-70 months). 6 patients survived free of disease. One patient was subject to local recurrence after one year. One patient died from distal metastasis after three years. No infection, prosthesis loosening and breakage occurred. The MSTS score was 18~27. Our study suggest 3D printing implants might be a promising approach for precision reconstruction and long-term stability.

1 Introduction

Primary bone malignant tumors in the pelvis area account for 3-4% of all malignant bone tumors[1, 2]. In the past, most malignant tumors in the pelvis were treated with hindquarter amputation with poor functional outcome and quality of life. With improvements in chemotherapy, pre-operative imaging and surgical techniques, limb salvage surgery has become a more popular treatment option[3]. However, the limb-preserving procedure is still a challenge, especially when the tumors involves the acetabulum.

Currently, a number of techniques have been described for the reconstruction of a peri-acetabular defect caused by tumor resection, including massive allograft, megaprotheses implantation, saddle prosthesis, iliofemoral arthrodesis, pseudarthrosis, allograft-prosthetic composite and endoprotheses. However, these different methods have resulted in a high complication rate, such as loosening, dislocation, nonunion and infection which would lead to the failure of reconstruction and subsequent

removal of allograft or prosthesis. Moreover, the mortality and recurrence rates are still relatively high[4, 5].

To investigate an effective method to reconstruct peri-acetabular defect, a novel 3D printing individualized acetabular prosthesis was designed and used to reconstruct the II or type II+III defect of the pelvis in eight consecutive patients with peri-acetabular tumors from December 2010 to May 2015. Here we report our experience with these eight consecutive patients who underwent such a reconstruction.

2 Materials and methods

Between December 2010 to May 2015, eight patients (6 male and 2 female, mean age 46.2 years) with peri-acetabular tumor were included. Five patients had chondrosarcoma, 2 had giant cell tumor of the bone, and 1 had malignant recurrent neuroectodermal tumor. All lesions involved the acetabulum in Enneking's zone II or zones II+III and were Enneking stage 2B. The median follow-up was 58 months.

Pre-operative CT and MRI image data of the patients were obtained and imported into Simpleware software 4.3 (Simpleware, England) for fusion and pre-operative planning (Fig.1). A simulated tumor resection was performed in Simpleware and the 3D model of the excised pelvis was transferred in stereo lithography (STL) format to UG NX7.5 software (Siemens, Germany) to design the individual prosthesis. In our study, all of the screws were manufactured by computer-assisted manufacture (CAM) techniques. The individual prostheses were manufactured by 3D metal printing techniques.

Five of the patients undergone the surgery using computer assisted navigation system (CANS). Three of the patients undergone the surgery assisted by osteotomy guide template (Fig.2). All the patients were treated for routine prevention of infection and deep vein thrombosis. Adjuvant therapy was determined according to the pathological diagnosis of the peri-acetabular tumor.

Patients were followed up on 3, 6 and 12 months postoperatively, and annually thereafter. Physical examination, routine pelvic X-ray, selectively pelvic and chest CT scan were performed to observe whether the peri-acetabular tumor recurrence and metastasis or not. Functional outcome following reconstruction was assessed by using the Musculoskeletal Tumor Society (MSTS) evaluation system

3 Results

The mean follow-up period was 37.5 months (range, 5-70 months). 6 patients survived free of disease. One patient was subject to local recurrence after one year. One patient died from distal metastasis after three years. One case suffered dislocation of hip joint on the second day after surgery because of the unsuitable movement. And the manual closed reduction of the hip joint was carried out. Two patients presented deep venous thrombosis postoperatively. One healed after thrombolytic therapy in 3 months. The other was treated with the filter in half a month after surgery. No infection, prosthesis loosening and breakage occurred. The MSTS score for the hip function was 18~27. The mean MSTS rating was 71.4%. Four patients had excellent outcome and 4 had good outcome.

4 Discussion

The tumor resection with solely free hand lacks accuracy, especially for the peri-acetabular tumors. The complex three-dimensional geometry of the pelvic bone aggravated the hand-controlled cutting errors, leading to high recurrence rate or difficulty in reconstruction[6]. Local recurrence is the most

concern when performing in the limb-salvage resection[7]. Local tumor control was influenced significantly by the surgical margin achieved. Thus, peri-acetabular tumor resection must be highly accurate and requires detailed preoperative planning. Previous studies reported that osteotomy guide template could simplify the process of tumor resection and the later prosthesis implantation[8]. However, few studies reported the clinical utility of osteotomy guide template technology in treating the peri-acetabular tumors. In our study, three patients undergone the surgery assisted by osteotomy guide template. The results showed the resection of peri-acetabular tumor and the reconstruction with prosthesis were accurate. The pathological examination confirmed that the tumors was completely resected. There were no tumor cell discovered on the margin of the resection level.

The patients in our study who undergone the reconstruction with the individualized prosthesis were followed up for 48-72 months and had favorable outcome and hip function after surgery. One patient who had chondrosarcoma died from pulmonary metastasis after three years, postoperatively. Other seven patients survived free of disease. The survival rate was 87.5%. No patients had local recurrence. All the patients were satisfied with the treatments. Four (50%) of the patients were able to walk almost normally and do running in short distance, and had normal flexion and extension of the hip. Two(25%) of the patients had mild lameness in their lower limb. There were about 10 degree difference of flexion in the operated hip compared with the opposite normal hip. The other two (25%) patients exhibited moderate lameness in their lower limb and occasionally walked with crutches with slight pain. They had flexion of the hip of about 60 degrees.

5 Conclusions

Accurate tumor resection and precise reconstruction with 3D printing individualized prosthesis can be achieved by CANS or guide plate. 3D printing implants might be a promising approach for precision reconstruction and long-term stability.

6 Reference

- [1] A. Hillmann, C. Hoffmann, G. Gosheger, R. Rodl, W. Winkelmann, T. Ozaki, Tumors of the pelvis: complications after reconstruction, *Arch Orthop Trauma Surg* 123(7) (2003) 340-4.
- [2] R.J. Wirbel, M. Schulte, W.E. Mutschler, Surgical treatment of pelvic sarcomas: oncologic and functional outcome, *Clin Orthop Relat Res* (390) (2001) 190-205.
- [3] R.J. Grimer, C.R. Chandrasekar, S.R. Carter, A. Abudu, R.M. Tillman, L. Jeys, Hindquarter amputation: is it still needed and what are the outcomes?, *Bone Joint J* 95-B(1) (2013) 127-31.
- [4] W. Guo, D. Li, X. Tang, Y. Yang, T. Ji, Reconstruction with modular hemipelvic prostheses for periacetabular tumor, *Clin Orthop Relat Res* 461 (2007) 180-8.
- [5] P.K. Jaiswal, W.J. Aston, R.J. Grimer, A. Abudu, S. Carter, G. Blunn, T.W. Briggs, S. Cannon, Peri-acetabular resection and endoprosthetic reconstruction for tumours of the acetabulum, *J Bone Joint Surg Br* 90(9) (2008) 1222-7.
- [6] O. Cartiaux, P.L. Docquier, L. Paul, B.G. Francq, O.H. Cornu, C. Delloye, B. Raucant, B. Dehez, X. Banse, Surgical inaccuracy of tumor resection and reconstruction within the pelvis: an experimental study, *Acta Orthop* 79(5) (2008) 695-702.
- [7] K.H. Shin, B.T. Rougraff, M.A. Simon, Oncologic outcomes of primary bone sarcomas of the pelvis, *Clin Orthop Relat Res* (304) (1994) 207-17.
- [8] B.M. Holzappel, H. Pilge, P.M. Prodinger, A. Toepfer, S. Mayer-Wagner, D.W. Hutmacher, R. von Eisenhart-Rothe, M. Rudert, R. Gradinger, H. Rechl, Customised osteotomy guides and endoprosthetic reconstruction for periacetabular tumours, *Int Orthop* 38(7) (2014) 1435-42.

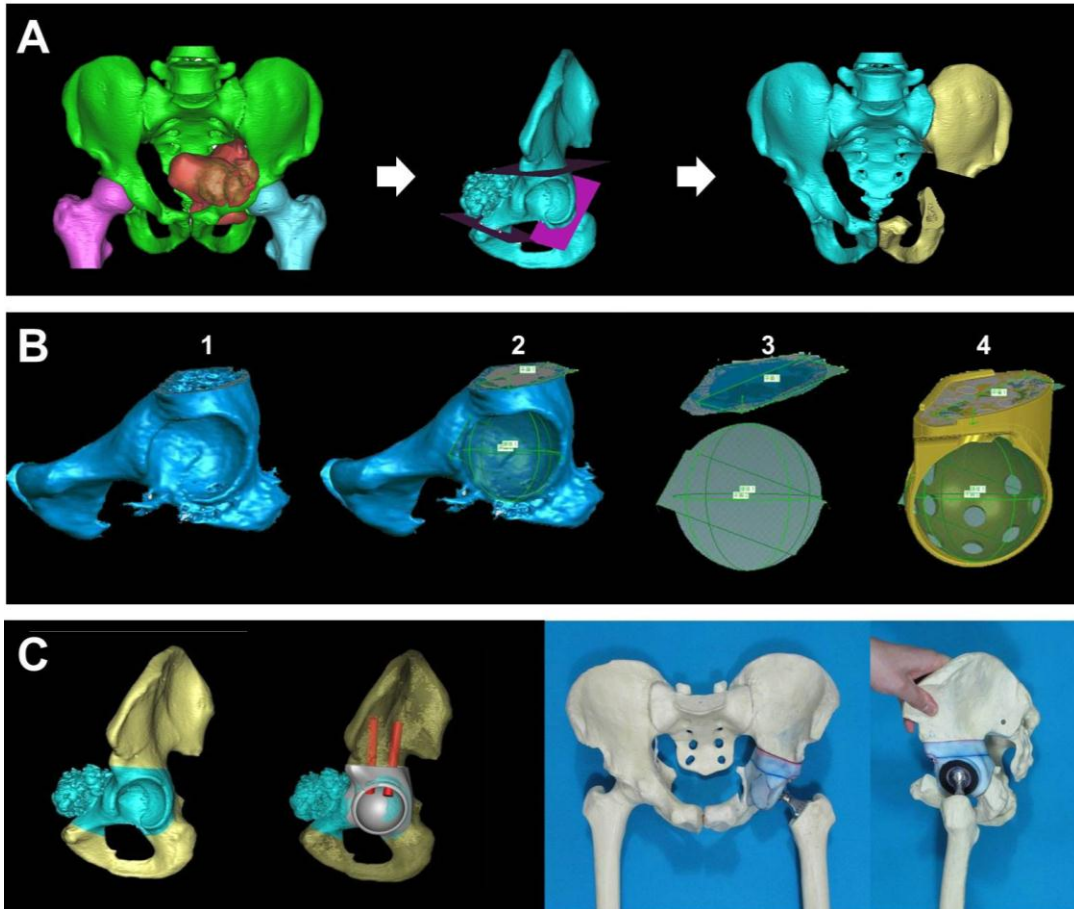


Fig.1 A. The boundaries of the resection was determined and a simulated tumor resection was performed in Simpleware; B. Design procedure of the individual prosthesis; C. Validation of the individual prosthesis by computer and 3D printing model.

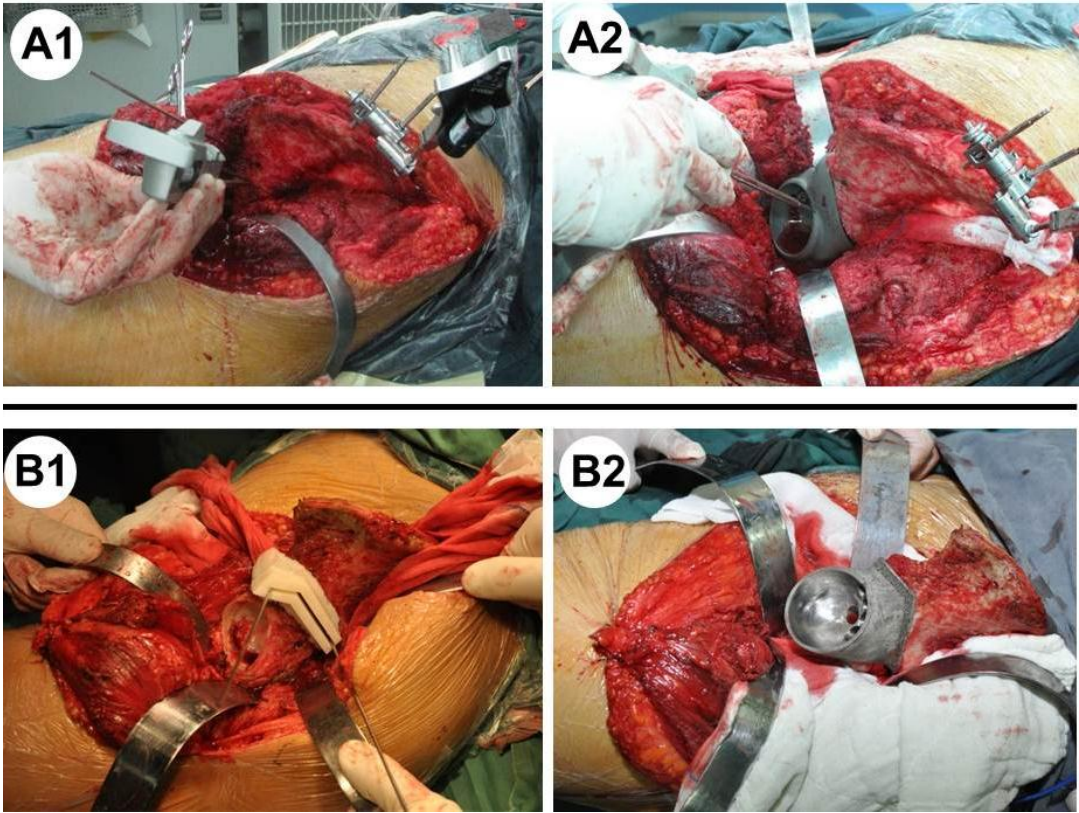


Fig.2 A1, A2. Tumor resection and installation of the individual prosthesis using computer assisted navigation system (CANS). B1, B2. Tumor resection and installation of the individual prosthesis using 3D printing guide template.