



NOFUSS: Navigated Orthopaedic Fixation using Ultrasound System

Prashant U. Pandey¹, Emily K. Bliven¹, Pierre Guy², Kelly A. Lefaiivre², and Antony J. Hodgson³

¹ School of Biomedical Engineering, University of British Columbia, Vancouver, BC, Canada
prashant@ece.ubc.ca

² Department of Orthopaedics, University of British Columbia, Vancouver, BC, Canada

³ Department of Mechanical Engineering, University of British Columbia, Vancouver, BC, Canada

Abstract

Fractures of the sacroiliac joint often require treatment through internal fixation. This procedure is typically guided by the use of intraoperative fluoroscopy, using an untracked C-arm device. However, this involves ionizing radiation exposure and the possibility of screw malplacement. We introduce the Navigated Orthopaedic Fixation using Ultrasound System (NOFUSS): an ultrasound (US) based end-to-end system for providing real-time navigation for iliosacral screw (ISS) insertions. Our system consists of an US imaging device and an optical tracking camera, together with computational algorithms for automatic processing of intraoperative data. In a cadaver trial of 6 specimens, we found that the ISS insertions performed using NOFUSS demonstrated accuracy comparable to conventional fluoroscopy guidance in the three specimens for which we could obtain good ultrasound images, reduced insertion time, and required no ionizing radiation.

1 Introduction

Pelvic fractures involving sacroiliac joint disruption require surgical treatment. This surgery involves reducing any displaced bone fragments, followed by percutaneous fixation of the sacroiliac joint using iliosacral screws (ISS). Intraoperative fluoroscopic imaging is typically used to provide guidance during fixation, which is achieved through the use of a C-arm fluoroscope device. However, intraoperative fluoroscopy leads to significant ionizing radiation exposure in the operating room, especially as numerous images have to be collected for fracture reduction and fixation. Each ISS insertion in a pelvic fracture case has been reported to result in 2 - 11 minutes of radiation exposure [3, 6]. Accumulation of radiation by the surgical team over years of exposure can result in a 2.9-fold increased risk of developing cancer [13, 2] and cataracts [4]. Moreover, placing ISSs is challenging given the narrow, often dysmorphic, sacral bone passage through which each screw must be placed. Using 2D fluoroscopy to guide an inherently 3D task of inserting ISSs can lead to inaccurate screw positioning. The rate of screw malplacement can be as high as 13% [5] when using fluoroscopy, and studies have estimated that 16% of ISS have resulted in iatrogenic complications [12].

On the other hand, ultrasound (US) offers the potential to image bone surfaces without ionizing radiation and has real-time 3D imaging capabilities. Previous research has established that US can accurately localize bone surfaces in humans, using rapid image segmentation algorithms [10]. In this study, we present and evaluate in cadaver tests the Navigated Orthopaedic Fixation using Ultrasound System (NOFUSS), a fully integrated system for navigated ISS insertions based on intraoperative US imaging and automated US bone segmentation.

2 Materials and Methods

NOFUSS is a computer-assisted surgical system, consisting of multiple integrated hardware and software components to provide appropriate navigation for ISS insertions. A surgical plan, based on the preoperative CT scan, was used to guide the navigation targets intraoperatively. NOFUSS combines existing US imaging and optical tracking devices, and builds on previously developed image analysis models and visualization techniques [7, 8, 9] to provide automated and radiation-free ISS insertion navigation. An overview of the NOFUSS architecture, hardware components, and use is illustrated in Figure 1.

To evaluate the NOFUSS system, we performed surgical ISS insertions on 6 human cadaver specimens. For each specimen, we inserted one screw at the S1 and S2 levels each with conventional fluoroscopic imaging on one randomly-assigned side, and using NOFUSS on the contralateral side. Tracked US sweeps were first collected from the specimen with respect to the rigid marker inserted in the patient. A minimum of three sweeps were required from each pelvic specimen, one each from the right anterior-superior iliac spine (ASIS) and left ASIS, and one from the superior pubic rami and pubic symphysis. The tracked US images were automatically segmented, reconstructed, and rigidly registered to the preoperative CT scan using previously developed techniques [7, 8]. The surgeon then proceeded to align the tracked surgical wire guide with the ISS plan at the S1 vertebral level, using the predefined visualization displayed on the monitor. Once aligned, the surgeon held the wire guide on target while inserting a 2.8 mm diameter k-wire (DePuy Synthes, Raynham, Massachusetts, United States) through the guide and into the bone using a surgical drill. The surgeon placed a 7.3 mm diameter ISS screw (DePuy Synthes, Raynham, Massachusetts, United States) over the inserted k-wire, using a manual surgical screwdriver to tighten the screw in place.

Our control methodology was using fluoroscopic imaging, as it is the current standard-of-care for pelvic ISS insertions. We used an Arcadis Orbic mobile C-arm (Siemens AG, Munich, Germany) to collect planar radiographs from specimens. The orthopaedic surgeon and an assistant manually positioned the C-arm around the specimen as required. X-rays were displayed on the C-arm device’s monitor, and these were used to guide the k-wire and ISS insertions. No navigation technology was used. Using a postoperative CT scan, we calculated the screw insertion error at the bone entry location and the rotational error in comparison to the preoperative surgical plan, and whether the inserted screw had breached the cortical bone surface. We also measured the overall radiation exposure, screw insertion time, and setup time for each method. Results were compared using the Wilcoxon Signed-Rank statistical test, and Fisher’s exact test was used to compare the number of statistical breaches.

3 Results

Procedures on six cadavers yielded a total of 24 ISS insertions. The median screw entry error for the NOFUSS was 8.4 mm compared to 7.5 mm with fluoroscopy with no statistically significant

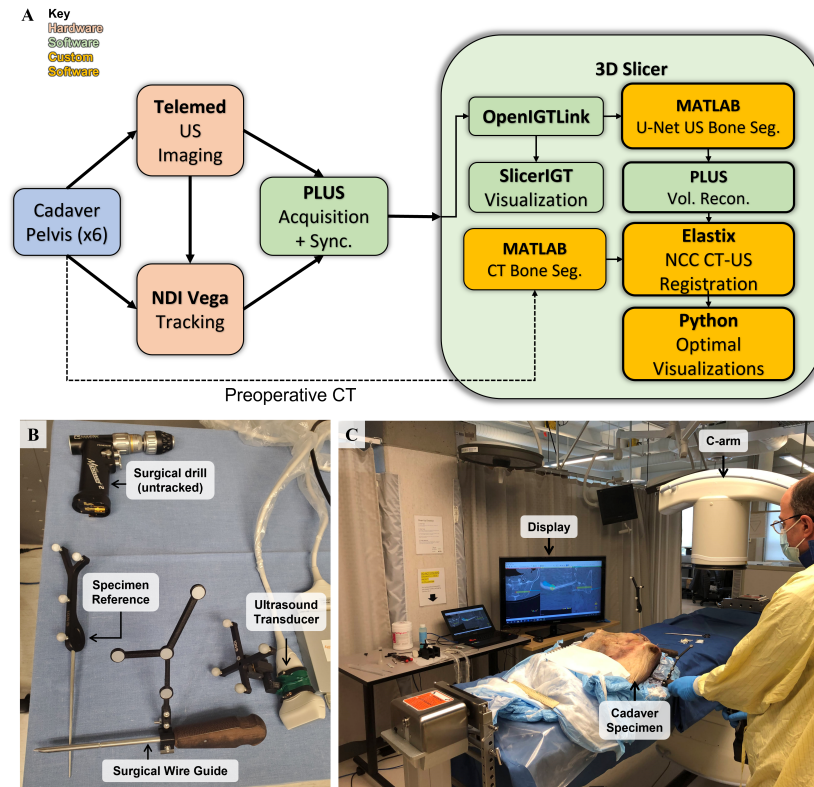


Figure 1: **A:** Overview of the 'Navigated Orthopaedic Fixation using Ultrasound System' (NOFUSS) architecture. Hardware components include the Northern Digital Inc. (NDI) Vega Tracking Camera and Telemed US system. Software components include open source frameworks of PLUS, 3D Slicer, SlicerIGT, along with custom software written for bone surface segmentation in US and CT, US-CT intensity-based registration, and visualizations. **B:** Devices and tools tracked in NOFUSS using passive reflective markers. **C:** NOFUSS being used by the surgeon during a cadaver specimen insertion.

difference ($p = 0.52$), and the median angulation errors were 1.4° and 4.4° for NOFUSS and fluoroscopy respectively, which did achieve statistical significance ($p = 0.001$). NOFUSS resulted in 6 (50%) breaches, compared to 2 (16.7%) in fluoroscopy, though this difference did not achieve statistical significance ($p = 0.19$).

We observed that the US image quality varied considerably across the six specimens, with three cadavers generating markedly poorer images than the other three, possibly due to extended frozen storage. Restricting our analysis to the three cadavers (12 screw placements) that demonstrated image quality more similar to what we would expect in live patients, the measured measured entry errors were 3.6 mm and 8.1 mm respectively for NOFUSS and fluoroscopy ($p = 0.06$), with 1 (16.7%) and 2 (33.3%) breaches respectively ($p = 1$). Screw entry errors and rotational errors are plotted in Figure 2.

The median insertion time was 7 min 37 s and 12 min 37 s per screw for NOFUSS and fluoroscopy respectively ($p = 0.002$). There was no statistically significant difference observed between the setup times for either methodology, with a median setup time of 13 min 8 s for

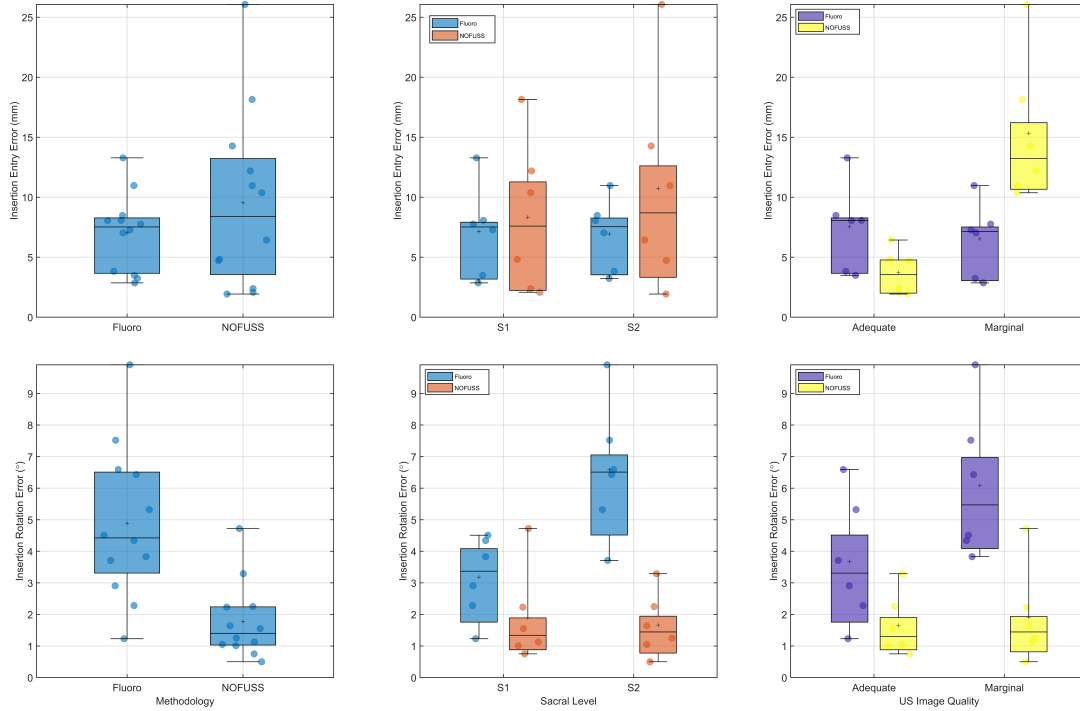


Figure 2: Plot of all screw insertion errors. Top row left to right: Entry errors grouped by methodology, sacral level, and US image quality. Bottom row left to right: Rotation errors grouped by methodology, sacral level, and US image quality.

NOFUSS and 11 min 54 s for fluoroscopy ($p = 1$).

We measured a median radiation exposure time of 2 min 44 s (95% CI: 1 min 53 s – 3 min 10 s) for fluoroscopic insertions per specimen, as reported by the internal radiation exposure counter on the C-arm device. There was no ionizing radiation exposure for insertions performed with NOFUSS, as the surgeon did not use the C-arm to guide the insertions.

4 Discussion And Conclusion

We demonstrated the feasibility of executing ISS insertions in an end-to-end fashion using NOFUSS on six human cadaver specimens, and showed that it is comparable to the conventional fluoroscopy-guided surgery in terms of accuracy and time requirements. We also found that NOFUSS resulted in better control over angulation than conventional fluoroscopic guidance. We believe these results demonstrate that NOFUSS can serve as an US-based framework for eliminating radiation and improving accuracy of complex orthopaedic internal fixations.

Compared to existing navigation systems for ISS insertions, such as 3D fluoroscopy [1] and intraoperative CT [11], NOFUSS provides comparable accuracy and likely more time-efficient navigation while substantially reducing or potentially eliminating reliance on intraoperative ionizing radiation. To the best of our knowledge, NOFUSS represents the first demonstration of an end-to-end US-based navigation system for fixation of pelvic fractures and the sacroiliac joint.

References

- [1] Daniel Behrendt, Maria Mütze, Hanno Steinke, Martin Koestler, Christoph Josten, and Jörg Böhme. Evaluation of 2D and 3D navigation for iliosacral screw fixation. *International Journal of Computer Assisted Radiology and Surgery*, 7(2):249–255, March 2012.
- [2] Loretta B. Chou, Christopher A. Cox, Joanna J. Tung, Alex H.S. Harris, Daria Brooks-Terrell, and Weiva Sieh. Prevalence of Cancer in Female Orthopaedic Surgeons in the United States. *The Journal of Bone and Joint Surgery-American Volume*, 92(1):240–244, January 2010.
- [3] Florian Gras, Ivan Marintshev, Arne Wilharm, Kajetan Klos, Thomas Mückley, and Gunther O Hofmann. 2D-fluoroscopic navigated percutaneous screw fixation of pelvic ring injuries - a case series. *BMC Musculoskeletal Disorders*, 11(1):153, December 2010.
- [4] Roman A. Hayda, Raymond Y. Hsu, J. Mason DePasse, and Joseph A. Gil. Radiation exposure and health risks for orthopaedic surgeons. *Journal of the American Academy of Orthopaedic Surgeons*, 26(8):268–277, April 2018.
- [5] J F Keating. Early fixation of the vertically unstable pelvis: The role of iliosacral screw fixation of the posterior lesion. *Journal of Orthopaedic Trauma*, 13(2):107–113, February 1998.
- [6] K. A. Lefaivre, A. J. Starr, B. P. Barker, S. Overturf, and C. M. Reinert. Early experience with reduction of displaced disruption of the pelvic ring using a pelvic reduction frame. *The Journal of Bone and Joint Surgery. British volume*, 91-B(9):1201–1207, September 2009.
- [7] Prashant Pandey, Pierre Guy, Antony J. Hodgson, and Rafeef Abugharbieh. Fast and automatic bone segmentation and registration of 3D ultrasound to CT for the full pelvic anatomy: A comparative study. *International Journal of Computer Assisted Radiology and Surgery*, 13(10):1515–1524, May 2018.
- [8] Prashant U. Pandey, Pierre Guy, and Antony J. Hodgson. Can uncertainty estimation predict segmentation performance in ultrasound bone imaging? *International Journal of Computer Assisted Radiology and Surgery*, 17(5):825–832, May 2022.
- [9] Prashant U. Pandey, Pierre Guy, Kelly A. Lefaivre, and Antony J. Hodgson. What are the optimal targeting visualizations for performing surgical navigation of iliosacral screws? A user study. *Archives of Orthopaedic and Trauma Surgery*, August 2021.
- [10] Prashant U. Pandey, Niamul Quader, Pierre Guy, Rafeef Garbi, and Antony J. Hodgson. Ultrasound Bone Segmentation: A Scoping Review of Techniques and Validation Practices. *Ultrasound in Medicine & Biology*, 46(4):921–935, April 2020.
- [11] Kuo Ti Peng, Yen Yao Li, Wei Hsiu Hsu, Meng Huang Wu, Jen Tsung Yang, Chu Hsiang Hsu, and Tsung Jen Huang. Intraoperative computed tomography with integrated navigation in percutaneous iliosacral screwing. *Injury*, 44(2):203–208, February 2013.
- [12] J. Tonetti, C. Cazal, A. Eid, A. Badulescu, T. Martinez, H. Vouaillat, and P. Merloz. Lésions neurologiques des fractures de l’anneau pelvien. *Revue de Chirurgie Orthopédique et Réparatrice de l’Appareil Moteur*, 90(2):122–131, March 2004.
- [13] Thurman B. Wenzl. Increased Brain Cancer Risk in Physicians with High Radiation Exposure. *Radiology*, 235(2):709–711, May 2005.